Imaging performed by

IntraPet Imaging

IntraPet.com

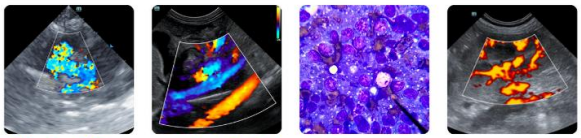

Clinical Sonography & Telecytology

Educational Teleconsultation Services™

SonoPath

FOSTERING THE ART OF VETERINARY MEDICINE™

SonoPath.com info@sonopath.com 1.800.838.4268

DATE

3.3.26

PATIENT

Alexis Jones

SPECIES

Feline

BREED

Egyptian Mau

SEX

FS

AGE

7.3.13

WEIGHT

12.45lbs

INTERPRETED BY

Maggie Machen Lamy, DVM, DACVIM (Cardiology)

HOSPITAL NAME

Chadwell AH

REFERRING VET

Dr. Gold

INVOICE

47074

PRESENTING CLINICAL SIGNS

History: Grade 2-3/6 heart murmur.
-Pertinent abnormal PE/Chem/CBC/UA Results: Mild azotemic, BNP 98.
-Current medications: None.
-Blood Pressure: 135mmHg
-Sedation used: Not required to complete full diagnostic ultrasound.
-Pertinent previous ultrasound results: No previous.
-STAT: Not requested.
Imaging performed by: Stephanie Warga RDCS, RVT.

ECHOCARDIOGRAM FINDINGS

2D, m-mode, color flow and doppler imaging is available. The left ventricular wall is normal in dimension. There is a mildly hyperechoic endocardium consistent with fibrosis. The papillary muscles are normal. The endocardium also appears remodeled. The left atrium is normal in size. The right atrium is normal in size. Moderate TR. Borderline velocity. The right ventricle appears normal. The mitral valve is normal in structure and mobility. Blood flow through both the LVOT and RVOT is normal in velocity. No pleural or pericardial effusion seen. No obvious cardiac tumors.

CARDIAC CHART

FELINE CARDIAC PARAMETERS	BODY WEIGHT (kg)	HR (BPM)	IVSd (cm) (Moise, Pipers)	LVIDd (cm) (Moise, Pipers)	LVWd (cm) (Moise, Pipers)	FS (%)	EF (%)
NORMAL PARAMETER	------	150-240	3.5-0.55	<2 (mean 1.5)	3.5-0.55	35-67	80-100
PATIENT	5.6	NM	0.48	1.2	0.46	57	90

FELINE CARDIAC PARAMETERS	LA/AO (Boon)	LA/AO HEART BASE (Swe) (Abbott)	LA 2D short axis Base view (cm) (Abbott)	LVOT VEL (m/s)	RVOT VEL (m/s)	E max (m/s)
NORMAL	<1.5	<1.3	<1.2	<1.6	<1.3	<0.9
PATIENT	NM	1.3	1.2	1.6	0.9	NM

Adapted from June Boon, Veterinary Echocardiography,1998
Abbott J & MacLean H JVIM 2006;20: 111-119, Moise et al. Am J Vet Res 47:1476, 1986. Pipers et al. Am J Vet Res 40:882, 1979.

INTERPRETATION OF THE FINDINGS & FURTHER RECOMMENDATIONS

The only abnormality identified is moderate TR. TR in cats is typically benign/physiologic; however, the quantity is significant and concerning in this case. The velocity is borderline without significant pulmonary hypertension identified. The right atrium does not appear dilated at this time, indicating stability. The left heart is normal with no hypertrophy or LA seen and no additional issues are identified.

Given these findings, no medications are indicated.

Prognosis is guarded prior to assessing for progression.

Anesthetic risk is considered mild. With this degree of remodeling and diastolic stiffening, there is an elevated risk for fluid overload in this patient and judicious IV fluid use is recommended. Heart rate stimulating drugs such as atropine, glycopyrrolate or ketamine should be avoided unless medically necessary.

Recommend recheck echocardiogram in 6-12 months to assess for progression.

IMAGES

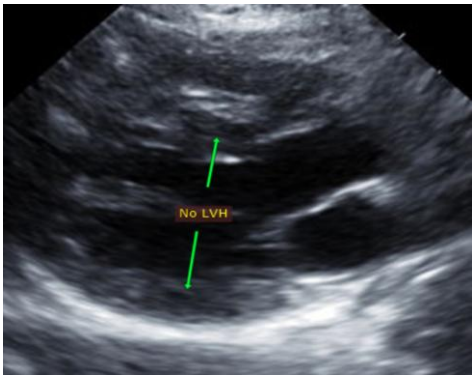

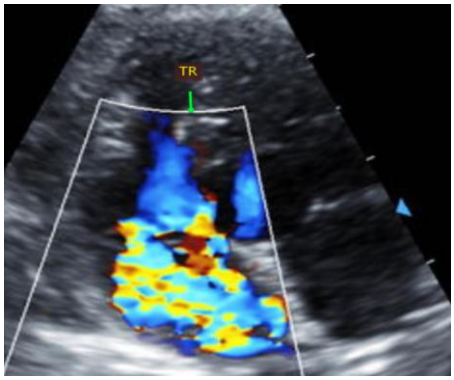

The information and recommendations provided are based on the images presented by the referring veterinarian. No evaluation can be communicated regarding pathology that was not visible in the image/video clips provided.

Thank you for this referral. This report was generated using transcription software, and minor dictation errors may be present. If the clinical or image interpretation does not parallel your findings or if I can be of any further assistance, please contact me.

Maggie Machen Lamy, DVM
Diplomate of the American College of Veterinary Internal Medicine (Cardiology)
info@sonopath.com